

Young H. Kim Cephalometric Analytic Procedure.

R. Silva Meza

Department of Orthodontics, Latin-American University ,ULA, México

Summary. The aim of this work was to describe step by step the analytic cephalometric method proposed by Dr Young H. Kim. This analysis has four components: Overbite Depth Indicator, Antero Posterior Dysplasia Indicator, Combination Factor and Extraction Index.

Key Words: Cephalometric, Kim analysis, Multiloop, MEAW

Introduction

The MEAW technique (Multiloop Edge-wise Arch Wire), is recognized for its efficiency in complex orthodontic treatments. This technique is based on individualized Multiloop arches, and is generally supported by the cephalometric analysis proposed by Dr. Young H. Kim. The aim of this work is to analyze and describe this cephalometric procedure to ease the understanding of this technique.

Review of literature. In 1974, Dr. Kim (KimYH.1974)after studying cephalograms of 119 patients with normal occlusions and 500 various malocclusions, selected fifteen cephalometric measurements to determine which produced the highest correlation with the incisal overbite depth. The Overbite Depth Indicator (ODI) is the arithmetic sum of the angle of the A-B plane to the mandibular plane and the angle of the Palatal plane to Frankfort horizontal plane. This study produced a norm of 74.5 degrees and with a standard deviation of 6.07°. A value of 68° or less indicates a skeletal openbite tendency (Katsaros C, Berg R, 1993). The correlation coefficient of the incisal

overbite depth and the ODI found its highest value (0.588) in the malocclusion sample of 500 individuals. Kim noticed that when the malocclusion fell within the range of normal overbite, the skeletal pattern generally did not deviate from that norm, regardless of the Angle classification. In this study he also noted that the sample had a range and severity of 11mm of overbite and -11mm of openbite. The normal occlusion sample showed ranges of 0.5 mm. To 4 mm. for the incisal overbite depth, with a mean value of 2.8 mm. The ODI analyzes and differentiates open bites and deep overbites with cephalometric values. Later, Kim and Vietas (Kim YH,Vietas J, 1978) analyzed cephalometric measurements in the horizontal plane and developed the Antero-posterior Dysplasia Indicator (APDI), which differentiates the anteroposterior relationship of the malocclusion pattern. Eventually, Kim combined both indicators to compare Class II, Division 1 malocclusions treated orthodontically with and without the extraction (Kim YH,1979) of permanent teeth.

This study led him to the development of the Combination Factor (CF) (Kim YH. Caulfield Z. Nahm Ch W. Chang YII, 1994),which joined two measure-

ments into one and gave clinicians a better comprehension of facial balance. Subsequently, he related the Combination Factor with the inter incisal angle

(IIA) and lip protrusion or retrusion. As he used this new cephalometric value to elect to extract teeth or not, he named it the Extraction Index (EI) ⁵.

Cephalometric References.

Cephalometric Points (Fig 1).

- A A Point: The deepest point on the curve of the maxilla between the anterior nasal spine and the dental alveolus.
- A1 Incisor: Incisal tip of the upper incisor
- AR Incisor: Root tip of the upper incisor.
- ANS Maxilla: Tip of the anterior nasal spine
- B B point: The deepest point on the anterior curve of the mandibular symphysis
- B1 Incisor: Incisal tip of the lower incisor
- BR Incisor: Root tip of lower incisor
- DT Chin: The point on the anterior curve of the soft tissue chin, tangent to the esthetic plane.
- En Nose: Tip of Nose.
- Mn Mid Nose: A mid point of nose
- Go Mandible: Gonion intersection of the ramus and mandibular planes (Cephalometric Go).
- Me Menton: A point located at the lowest point on the midline curve of the symphysis.
- N Nasion: A point at the anterior limit of the nasofrontal suture.
- O Orbitale: A point located at the lowest point on the external border of the orbital cavity, tangent to the Frankfort plane.
- PAC Posterior alar cartilage.
- PNS Maxilla: Tip of the posterior nasal spine.
- Pr Porion : A point located at the most superior point point of the external auditory meatus, tangent to the Frankfort plane.
- Pg Pogonion: Most anterior point on the midsagittal symphysis tangent to the Facial plane.

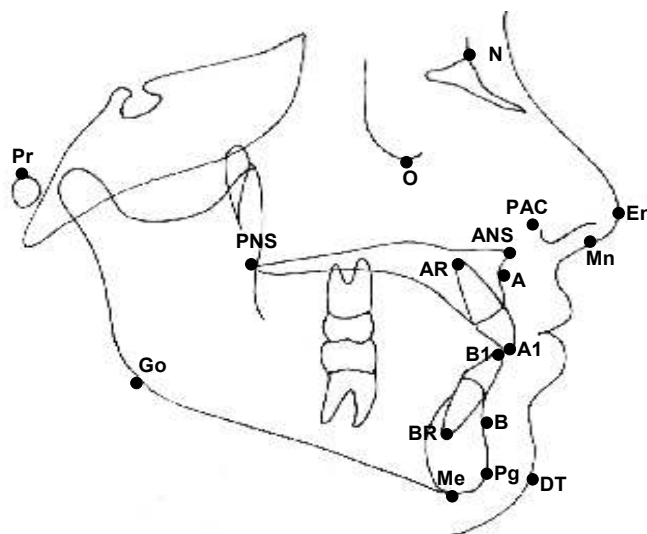


Fig.1. Cephalometric points.

Lateral Cephalometric Planes (Fig. 2)

1. Frankfort Horizontal Plane: From Porion to Orbitale (Po-O)
2. Facial plane: Nasion to Pogonion (N-Pg)
3. Mandibular plane: Gonion to Menton (Go-Me).
4. In case of marked antegonial notch, the concavity should be bisected for the mandibular plane
5. AB plane: A point to B point (A - B). Line from A to B points.
6. Palatal plane: Anterior Nasal Spine to Posterior Nasal Spine (ANS - PNS) The maxillary plane normally extends anteriorly to the base of the nose (posterior inferior part of the alar cartilage; PAC).
7. Esthetic line: For Caucasian people, it should be drawn from the midpoint of nose to tip of chin (Mn -DT), and for Asians, it should be drawn from the tip of nose to tip of chin (En - DT).
8. Incisal axes: Long axis of the incisors (A1-AR, B1 -BR).

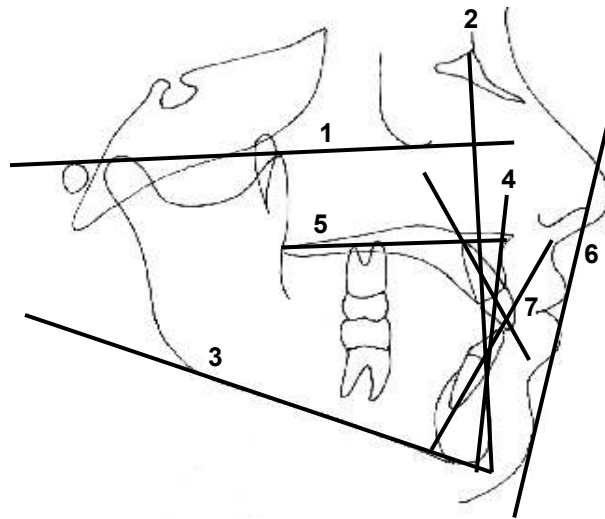


Fig.2. Lateral Cephalometric planes.

Measurements and interpretation.

This analysis has four components: 1. Overbite Depth Indicator, 2. Antero Posterior Dysplasia Indicator, 3. Combination Factor and 4. Extraction Index.

1. Overbite Depth Indicator (ODI).

Overbite Depth Indicator (ODI) is the arithmetic sum of the angle of the A-B plane to the mandibular plane and the angle of the Palatal plane to Frankfort horizontal plane (Fig. 3), and determines the vertical maxillo-mandibular relationship.

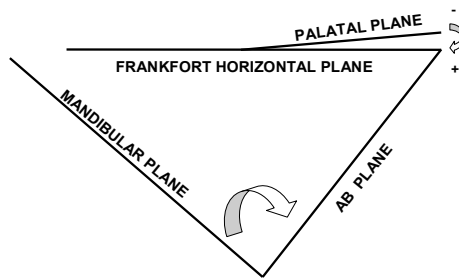


Fig. 3. Overbite Depth Indicator (ODI), is the arithmetic sum of two angles.

a) Mandibular Plane to A- B Plane Angle.

This angle is formed by the mandibular plane and AB plane (Fig. 4), measures 75.8° approximately and represents the facial cone, in accordance with the disposition of the structural facial components, the angle may be closed. An opened angle (Fig.5), is related to deep bite, meanwhile a closed angle is related to an open bite (Fig.6).

I. When the MP-AB angle is opened by shifting the mandibular plane (Fig.7).

Mandibular plane shifting to open the MP-AB angle is possible, when the posterior facial height is increased. This may be a result of the posterior cranial base slope (where the glenoid fossa is located), or the height of the mandibular ramus. It is also possible when the anterior facial height decreases, due to vertical deficiency of the nasomaxillary process, vertical deficiency on the mandibular symphysis, or by the mandibular anatomic shape (euryprosopic facial type), that may show a close gonial angle.

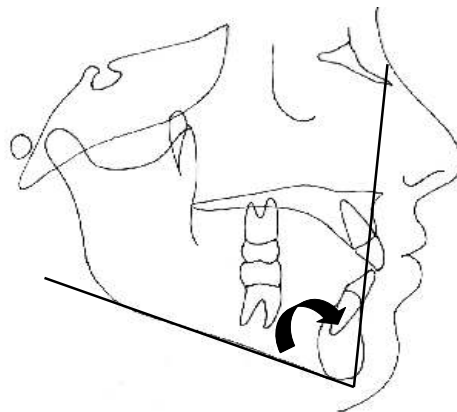


Fig.4. Mandibular Plane to AB Plane angle

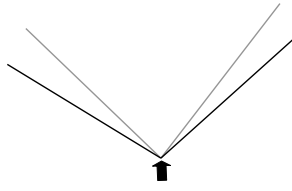


Fig.5. Open Angle = Deep Bite.

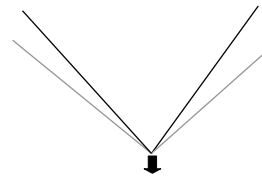


Fig.6. Closed Angle = Open Bite.

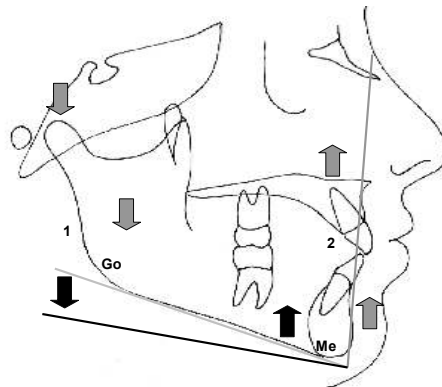


Fig.7

Fig.7. Mandibular Plane opened :1.Increased posterior facial height 2. Decreased anterior facial height . OPEN ANGLE = DEEP BITE

II. *When MP-AB angle is opened by shifting the AB plane* (Fig.8). AB plane shifting to open the MP-AB angle is possible when maxillary protrusion or mandibular retrusion exists.

This may be as a result of the posterior cranial base slope (where it's located the glenoid fossa), or by the mandibular ramus height. It is also possible when the anterior facial height is increased as a result of a vertical maxillary excess, vertical mandibular symphysis excess, or by the mandibular anatomic shape (leptoprosopic facial type), that may show an open gonial angle.

III. *When the MP - AB angle is closed by shifting the mandibular plane* (Fig.9) Mandibular plane shifting to close the MP-AB angle is possible when posterior facial height is decreased.

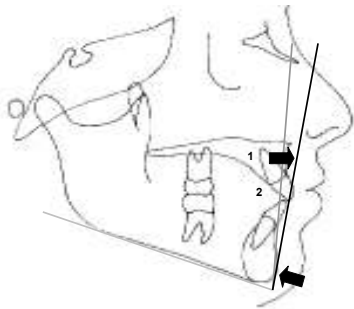


Fig. 8.

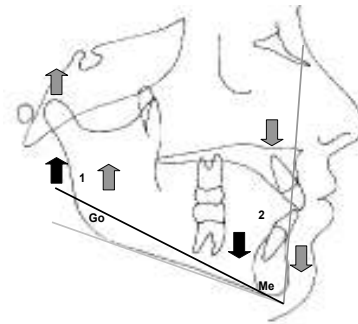


Fig.9.

Fig. 8 A-B Plane opened: 1 Maxillary protrusion. 2.Mandibular retrusion OPEN ANGLE = DEEP BITE.
 Fig.9. Mandibular Plane closed:1. Decreased posterior facial height. 2. Increased anterior Facial height
 CLOSED ANGLE = OPEN BITE

IV. When the MP - AB angle is closed by shifting the AB plane (Fig.10). AB plane shifting to close the MP-AB angle is possible when maxillary retrusion or mandibular protrusion exists.

tipped upward and forward and it is related to open bite, meanwhile the positive angle is related to deep bite (Fig.13).

b)Frankfort Horizontal Plane to Palatal Plane Angle.

2. Antero Posterior Dysplasia Indicator (APDI).

This angle is formed by Frankfort Horizontal plane and Palatal plane (Fig. 11), measures -2° approximately and represent the palatal position. A Positive angle indicates that the palate is tipped downward and forward. Negative angle (Fig.12), indicates that the palate is

The Antero Posterior Dysplasia Indicator (APDI), is the arithmetic sum of three angles: Frankfort Horizontal plane to Facial plane, A-B plane to the Facial plane and Frankfort plane. (Fig.14). APDI determines the horizontal maxillo-mandibular relationship (Class I,II, II

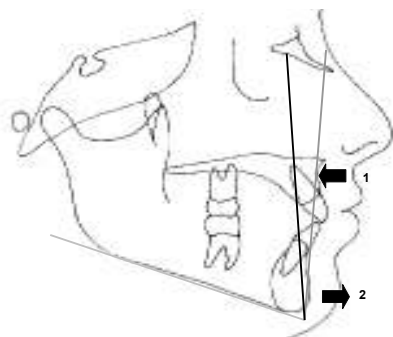


Fig 10.

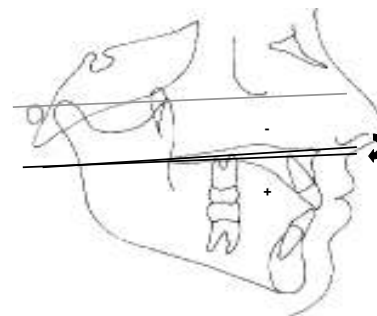


Fig 11

Fig. 10. A-B Plane closed: 1. Maxillary retrusion. 2.Mandibular protrusion. CLOSED ANGLE = OPEN BITE
 Fig.11 Frankfort Horizontal Plane to Palatal Plane angle

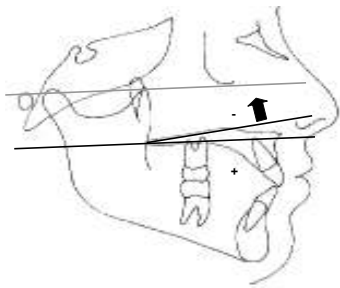


Fig. 12.

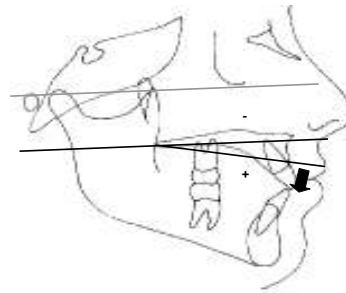


Fig. 13

Fig.12 Frankfort Horizontal Plane to Palatal Plane Negative angle. NEGATIVE ANGLE = OPEN BITE

Fig.13 Frankfort Horizontal Plane to Palatal Plane Positive angle POSITIVE ANGLE = DEEP BITE

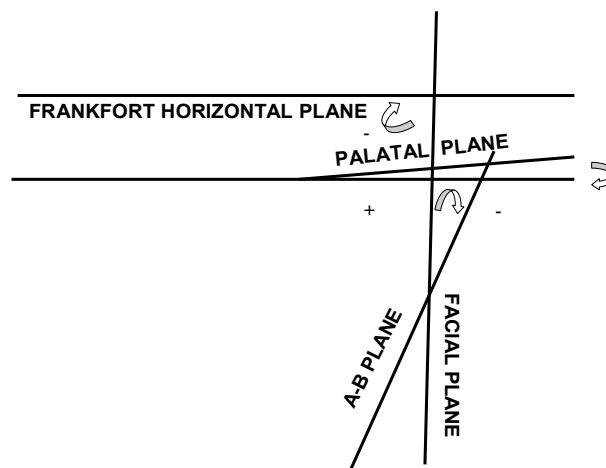


Fig. 14 Antero Posterior Dysplasia Indicator (APDI), is the sum of three angles.

a) Frankfort Horizontal plane to Facial plane (Facial Depth).

This angle is formed by Frankfort Horizontal plane and Facial plane (Fig. 15), measures $87^{\circ} \pm 3^{\circ}$, locates the chin horizontally, and determines if the skeletal class is due to the mandible. The opened angle is related to a prognathic mandible (Fig.16), meanwhile, the closed angle is related to retrognathic mandible (Fig.17).

b) Facial plane to AB plane .This angle is formed by Facial plane and AB plane (Fig.18), and determines the horizontal maxillo-mandibular relation-

ship (convexity). When a negative angle (Fig.19), indicates that the point A is forward in relation to point B, horizontally it is related to a Class II malocclusion. When a positive angle (Fig.20), indicates that point A is behind point B, horizontally, it is related to Class III malocclusion. To establish the facial convexity with the FP-AB angle, it is necessary to know the mandibular position (FH-FP). If the mandible is prognathic the FP- AB angle will be closed with a tendency to a positive angle (Cl III). Meanwhile, if the mandible is retrognathic, the convexity will be increased opening the angle with a Class II tendency.

c) Frankfort Horizontal Plane to Palatal Plane Angle.

This angle is obtained from the Frankfort Horizontal plane and the Palatal plane (Fig. 11) it measures approximately -2° and represents the palatal position. A negative angle

(Fig.21) indicates that the palate is tipped upward and forward. Horizontally, it is related to Class II malocclusions. A positive angle (Fig.22) indicates that the palate is tipped downward and forward. Horizontally, it is related to Class III malocclusions

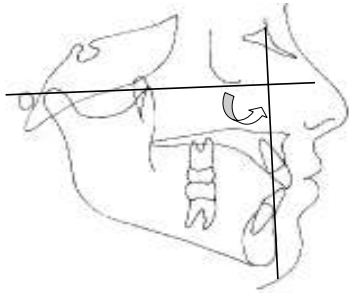


Fig 15

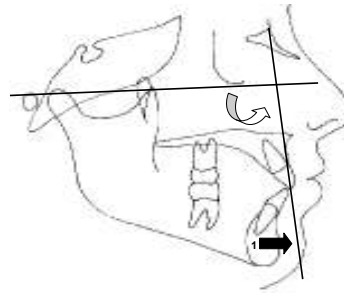


Fig. 16

Fig.15. Frankfort Horizontal plane to Facial plane angle (Facial Depth). Fig.16. Frankfort Horizontal Plane to Facial plan angle opened: 1. Prognathic mandible (CI III).

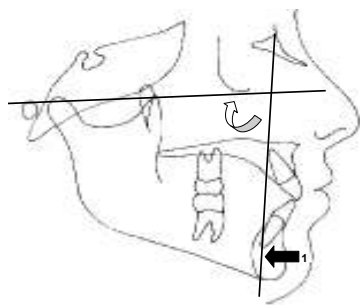


Fig. 17

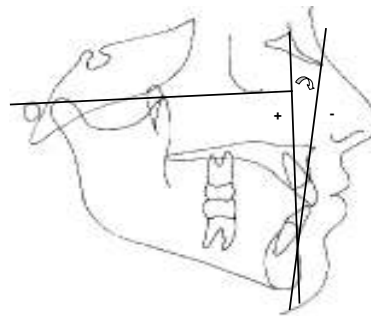


Fig.18

Fig.17. Frankfort Horizontal plane to Facial plane angle closed: 1. Retrognathic mandible (CI II)

Fig.18. Facial plane to AB plane angle (Convexity).

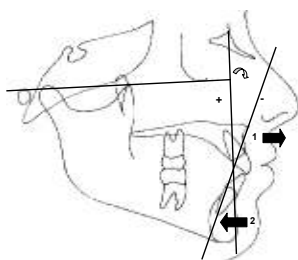


Fig. 19.

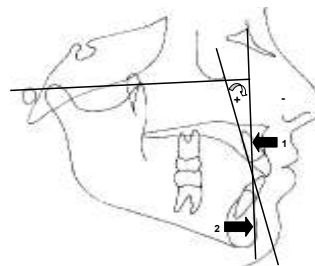


Fig. 20

Fig.19. Facial plane to A-B plane angle Negative: 1.Maxillary protrusion. 2.Mandibular retrusion: NEGATIVE ANGLE = CLASS II. Fig.20. Facial Plane to AB plane angle Positive: 1. Maxillary retrusion. 2.Mandibular retrusion: POSITIVE ANGLE = CLASS III.

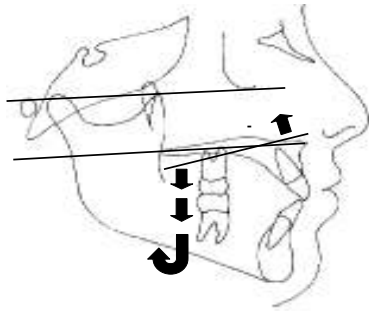


Fig. 21.

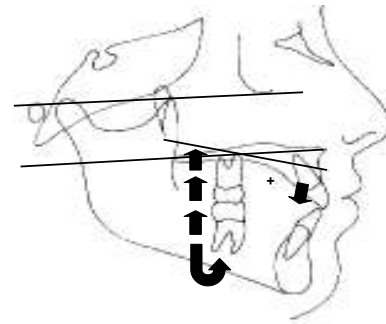


Fig.22 Fig.21.

Frankfort Horizontal plane to Palatal Plane angle. Negative:NEGATIVE ANGLE =CLASS II.Fig.22 FH-PP Positive angle: Class III: POSITIVE ANGLE = CLASS III

3..Combination Factor (CF)

This measurement is obtained by the sum of Overbite Depth Indicator (ODI), and Antero Posterior Dysplasia Indicator (APDI). The norm is 155.9° and represents the balance of both dimensions (Vertical-Horizontal). It is very useful in preparing treatment plan. In some patients we may observe that the vertical and horizontal components are beyond the norm; however, altogether they may be compensated. When the Combination Factor (CF), is under the norm (155.9°), the skeletal pattern tends to improve with dental extractions, but it is understood that we must analyze some other aspects to define this possibility. On the other hand, a Combination Factor higher than the norm (155.9°) will maintain a better relation when we don't extract any premolar teeth.

4. Extraction Index (EI)

"In orthodontics It is as bad to extract teeth when it is not necessary as when they are not extracted when it is necessary". Sometimes in orthodontic treatment some extractions, inclusive of healthy teeth are required. This is justified when this procedures are obtained organic occlusion characteristics, asymptomatic, autoprotected in balance and facial

harmony with the healthy function of an esthetic consequence. The decision to extract teeth in orthodontics has been a motive of discussion for almost a century and it shows that it is not a simple task. Nowadays, it is agreed that in some cases this procedure is adequate and in some cases it is inevitable. That is why the objectives are pursued, when extractions are performed, they must be precise and well supported with calculated results. Numerous factors other than the skeletal pattern influence the dentition: myofunctional imbalance, discrepancy in the relative dimension of the dentition to each arch dimension, discrepancy in relative tooth size, congenital absence of teeth, aberrant eruptive patterns and the presence and position of third molars are some of the common and contributory factors to malocclusions⁵.

Clinicians must also consider these features in conjunction with the Extraction Index before deciding to sacrifice teeth. it is convenient to review the following before deciding to extract :Which effect would the *expansion* produce? Which effect would the *protrusion or retrusion* produce? Is *molars distalization* possible? Is *"stripping"* possible ? Could the *combination* of these factors be feasible? Which *mechanics and anchorage* will be necessary? Do *patient*

and parents accept the extractions? Am I prepared to deal with any complications? What good results are we going to obtain with extractions? Is there any other alternative?

The **Extraction Index** gives us an objective way to evaluate whether or not to extract teeth for orthodontic treatments, considering the vertical and horizontal balance with two esthetical aspects: a) The lip position regarding the esthetic line, and b) the Interincisal position.

This measurement is obtained by the sum of Combination Factor and the Interincisal angle (IIA) and lip protrusion or retrusion. If the inter incisal angle (IIA) is smaller than the norm (130°) calculate the next formula ($130 - \text{IIA} \div 5 =$), If the IIA is greater

than the norm (130°) calculate the next formula ($\text{IIA} - 130 \div 5 =$). The distance between the lips and the esthetic line is measure in millimeters.

Acute Interincisal angles related to dental protrusion, indicating a tendency toward extraction. Obtuse Interincisal angles are related to dental retrusion leading to no extraction. A retrusive lip position is related to non-extraction and a protrusive lip position is related to extraction. (Kim YH, 1974)

When differences are observed in CF between the vertical and the horizontal components, there might be a possibility of modifying these differences by orthopedic or surgical means. In this case it is convenient to do the EI. Once that is done, the modifications to obtain a congruent result with a stable facial eststructure can be predicted.

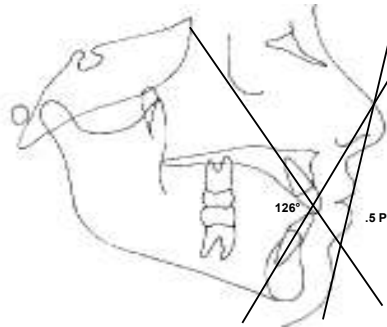


Fig. 23. Interincisal angle and lip position.

ODI-APDI-EI

PATIENT: _____ AGE _____ DATE _____

OVERBITE DEPTH INDICATOR (ODI)

1. Kim YH. Overbite Depth Indicator: with particular referente to anterior bite. Am J Orthod 1974;65:586-611

	CASE		
MP-AB			
FH-PP	+	>< OK	
FH-PP	-	< OPENED	
ODI 74.5° ± 6°	=	> CLOSED	

MP-AB = Mandibular plane to AB plane
 FH-PP = Frankfort Horizontal to Palatal plane

ANTEROPOSTERIOR DYSPLASIA INDICATOR (APDI)

2. Kim YH. Vietas J. Anteroposterior Dysplasia Indicator: And adjunct to cephalometric differential diagnosis. Am J Orthod 1978;73:619-633

FH-FP			
FP-AB	+		
FP-AB	-		
~	=		
FH-PP	+	>< CL I	
FH-PP	-	< CL II	
APDI 81.4° ± 3.7°	=	> CL III	

FH-FP = Frankfort Horizontal to Facial plane
 FP-AB = Facial Plane to AB plane

EXTRACTION INDEX (EI).

3. Kim YH. et al Overbite Depth Indicator, Anteroposterior Dysplasia Indicator., Combination factor and Extraction Index. MEAW 1994;1(1):81-104

ODI 74.5° ± 6°	~			
APDI 81.4° ± 3.7°	~	+		
CF 155.9°	IIA	=		
IIA >130 (IIA -130) ÷ 5		+		
IIA <130 (130 -IIA) ÷ 5		-		
LP- EL RETRUSIVE		+	><?	
LP- EL PROTRUSIVE		-	< EXT	
EI	~	=	> NO EXT	

ODI = Overbite Depth Indicator
 APDI = Anteroposterior Dysplasia Indicator
 CF = Combination Factor
 IIA = Interincisal Angle
 LP = Labial Position
 EL = Esthetic Line

	DATES:			
ODI	74.5° ± 6°			
APDI	81.4° ± 3.7°			
CF	155.9°			
IIA	130			
LP EL	RETRUSIVE			
LP EL	PROTRUSIVE			

Table 1 ODI,APDI,EI.

References.

- 1.Kim YH. Overbite Depth Indicator: With particular reference to anterior open bite. *American Journal of Orthodontics* 1974; 65:586-611.
- 2.Katsaros C, Berg R. Anterior open bite malocclusion: A follow up study of orthodontic treatment effects.*European Journal of Orthodontics* 1993; 15:273-280
- 3.Kim YH, Vietas J.Anteroposterior dysplasia indicator: An adjunct to cephalometric differential diagnosis. *American Journal of Orthodontics* 1978; 73:619-633.
- 4.Kim YH. A comparative cephalometric study on class II, Division 1, non-extraction and extraction cases. *Angle Orthodontist* 1979; 49:77-84.
- 5.Kim YH. Caulfield Z. Nahm Ch W. Chang YII. Overbite Depth Indicator, Anteroposterior Dysplasia Indicator, Combination Factor and Extraction Index. *The International Journal of the Multiloop Edgewise Arch Wire Technic and Research Foundation* Sep 1994; 1(1): 81-104.
- 6.Samson GS. Continuing education course: The Clinical Modification of Dentofacial Development (CMDD)



Dr Roberto Silva Meza is an orthodontist and clinical professor, Latin-American University, U.L.A.,México D.F.

Correspondence to:

Dr. Roberto Silva Meza

Address:

Roberto Gayol 1255-204

Col del Valle CP 03100

México 12 DF México

E-mail: bobsilva@prodigy.net.mx